



Optic nerve head recovery following the intraocular pressure – lowering surgery in the eye with early juvenile glaucoma – nine-year follow-up

Oporavak vidnog živca posle filtracione antiglaukomne operacije u oku sa ranim juvenilnim glaukomom tokom perioda praćenja od devet godina

Vujica Marković*†, Dragan Vuković*†, Ivan Marjanović*†,
Sanja Petrović Pajić*, Aleksandra Radosavljević*†,
Aleksandra Ilić*, Vesna Marić*†

Clinical Center of Serbia, *Clinic for Eye Diseases, Belgrade, Serbia; University of Belgrade, †Faculty of Medicine, Belgrade, Serbia

Abstract

Introduction. Congenital uveal ectropion (CEU) is a rare, non-progressive condition often accompanied with eyelid ptosis, anterior insertion of the iris, disgenesis of the irido-corneal angle and glaucoma. **Case report.** We present a case of a seven-year-old girl with a congenital unilateral uveal ectropion and a secondary glaucoma which had daily variations from 13 up to 50 mm Hg. The patient had no other abnormalities of the iris or underlying systemic diseases. Introduced local anti-glaucomatous therapy initially normalized intraocular pressure (IOP), but failed to provide long term normalisation. Trabeculectomy normalized the IOP which resulted in the reduction of the cup/disc ratio and restitution of neuroretinal rim. The rim area increased to 1.716 mm² (0.958 mm² preoperative) rim volume, was 0.666 mm³ (0.195 mm³ preoperative) while cup-disc (C/D) ratio decreased to 0.330 (0.626 preoperative) as well as linear C/D=0.574 (0.791 preoperative). Neuroreti-

nal rim (NR) was preoperatively preserved in the Ti segment, damaged in T, Ts, N, Ns segments, and borderline in the Ni segment. Postoperatively, neuroretinal rim was preserved in all segments. **Conclusion.** In the presented case trabeculectomy induced recovery of the nerve tissue of the optic nerve head which was confirmed by Haidelberg Retina Tomograph II (HRT II). The treatment results have been maintained during the follow-up period of nine years without topical or systemic antiglaucomatous therapy. Although CEU is a non-progressive and benign eye disease, associated glaucoma can cause severe optic nerve damage if not detected early and treated properly. As can be seen in the presented case, an adequate treatment can prevent and even reverse optic disc neuropathy.

Key words:

ectropion; uvea; congenital abnormalities; glaucoma; trabeculectomy; treatment outcome; child.

Apstrakt

Uvod. Kongenitalni ektropijum uvee je retko, neprogresivno stanje često praćeno ptozom, prednjom insercijom dužice, disgenozom irido-kornealnog ugla i glaukomom. **Prikaz bolesnika.** U radu je prikazana sedmogodišnja devojčica sa kongenitalnim ektropijumom uvee i sekundarnim glaukomom sa dnevnim skokovima pritiska do 50 mmHg. Bolesnica nije imala druge abnormalnosti dužice niti pridružene sistemske bolesti. Uvedena lokalna antiglaukomna terapija iako je dovela do početnog pada, nije dovela i do trajne normalizacije očnog pritiska (IOP). Filtraciona antiglaukomna operacija je dovela do trajne normalizacije IOP što je rezultovalo smanjenjem ekskavacije optičkog diska i opo-

ravkom neuroretinalnog oboda. Površina oboda se uvećala na 1,716 mm² sa preoperativnih 0,958 mm², zapremina na 0,666 mm³ sa preoperativnih 0,195 mm³, dok se ekskavacija smanjila sa 0,791 na 0,574. Neuroretinalni obod je preoperativno bio sačuvan samo u donjem temporalnom segment. Postoperativno, neuroretinalni segment je bio normalan u svim segmentima. **Zaključak.** Kod prikazane bolesnice trabekulektomija je dovela do oporavka optičkog nerva što je potvrđeno uz pomoć Haidelber Retina Tomograph II (HRT II) softvera. Tokom devetogodišnjeg perioda praćenja bolesnice nije koristila antiglaukomnu terapiju, pritisak je bio normalan, bez oštećenja optičkog nerva. Iako je kongenitalni ektropijum uvee neprogresivno i benigno oboljenje, pridruženi glaukom može da izazove ozbiljno

oštećenje očnog nerva ukoliko se ne otkrije i ne leči na vreme. Kao što može da se zaključi iz ovog prikaz bolesnika adekvatnim tretmanom može se sprečiti nastanak oštećenja, a čak i dovesti do oporavka vidnog živca.

Introduction

Congenital ectropion uveae (CEU) is a rare, nonprogressive condition insufficiently mentioned in the ophthalmologic literature.

Etiologically, uveal ectropion can be classified into two groups: acquired and congenital.

CEU is characterised by the ectropionated pigment epithelium layer on the front surface of the iris from the pupillary ruff, anterior insertion of the iris, dysgenesis of the iridocorneal angle and glaucoma.

Some studies have also found CEU joined with congenital anomalies and hereditary diseases.

Case report

In April 2007 a 6-year-old girl was referred to the Institute for Eye Diseases of Clinical Center of Serbia by a pediatric ophthalmologist for clinical examination due to an elevated intraocular pressure (IOP) in her right eye. Mother reported that about 3–4 ago, she started noticing wider right pupil, enlargement of the right eye and slightly lowered upper eyelid. The patient also had eye tenderness and pain with occasional and moderate redness and “bulging”.

Best corrected visual acuity (correction -1.25 Dsph = -1.75 Dcyl ax 14 degrees) on her right eye was 20/20. Her left eye visual acuity was 20/20. IOP measured by Goldmann Applanation Tonometer was 36 mmHg on the right, and 18 mmHg on her left eye. Horizontal corneal diameters were 11.5 mm on the right and 10.5 mm on the left eye. Ptosis of the right upper eyelid was evident as well as anisocoria with wider and slowly responsive right pupil. Slit lamp examination showed 2–3 mm wide zone of the uveal pigmented layer ectropion on the anterior iris surface which affected 360 degrees of the pupil margin. There were no signs of the newly formed blood vessels, tumors or other congenital anomalies (Figure 1).

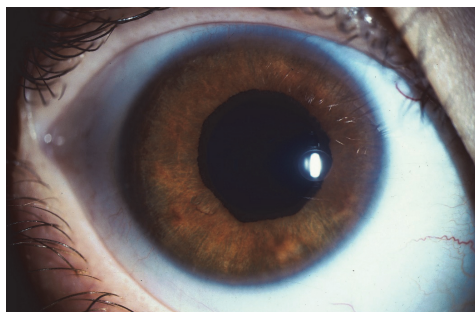


Fig. 1 – Slit lamp: Congenital uveal ectropion.

Gonioscopic findings on her right eye show a wide anterior chamber angle with anterior insertion of the iris of medium pigmentation – *aplasio ligamentum pectinatum* (Figure

Ključne reči:
ektropijum; uvea; anomalije; glaukom; trabekulektomija; lečenje, ishod; deca.

2). Left eye gonioscopy showed open, free and moderately pigmented iridocorneal angle.



Fig. 2 – Gonioscopic findings of the congenital uveal ectropion.

Red reflex was present in both eyes, without defects. Fundus examination showed excavation of the optic head with cup/disc (C/D) ratio 0.7/I, while left was C/D 0.2/I.

Ultrasound biomicroscopy (UBM) confirmed the results of the gonioscopy (Figure 3).

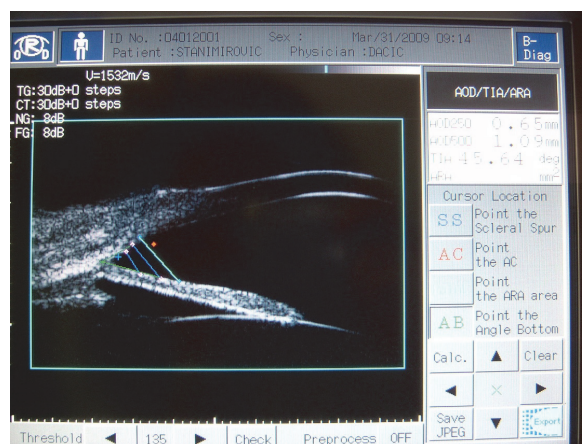

Fig. 3 – Ultrasound biomicroscopy (UBM) of the affected eye: trabecular iris angle 45.64°, angle opening distance 0.65 mm at 250 μm and 1.09 mm at 500 μm, trabecular-ciliary process distance 0.788 mm, iris-ciliary process distance 0.240 mm, anterior chamber depth 3.12 mm and iris thickness 0.322 mm.

Humphrey computerized perimetry was performed, but the results were invalid due to poor cooperation. As shown on the Figure 4 neuroretinal rim (NR) was damaged in nearly all segments. Disc area was 2.560 mm², rim area 0.958 mm² and rim volume = 0.195 mm³, C/D ratio was = 0.626, linear cup C/D = 0.791. Moorfields regression analysis was classified as “outside normal limits”. HRT II of the left eye showed no abnormalities.

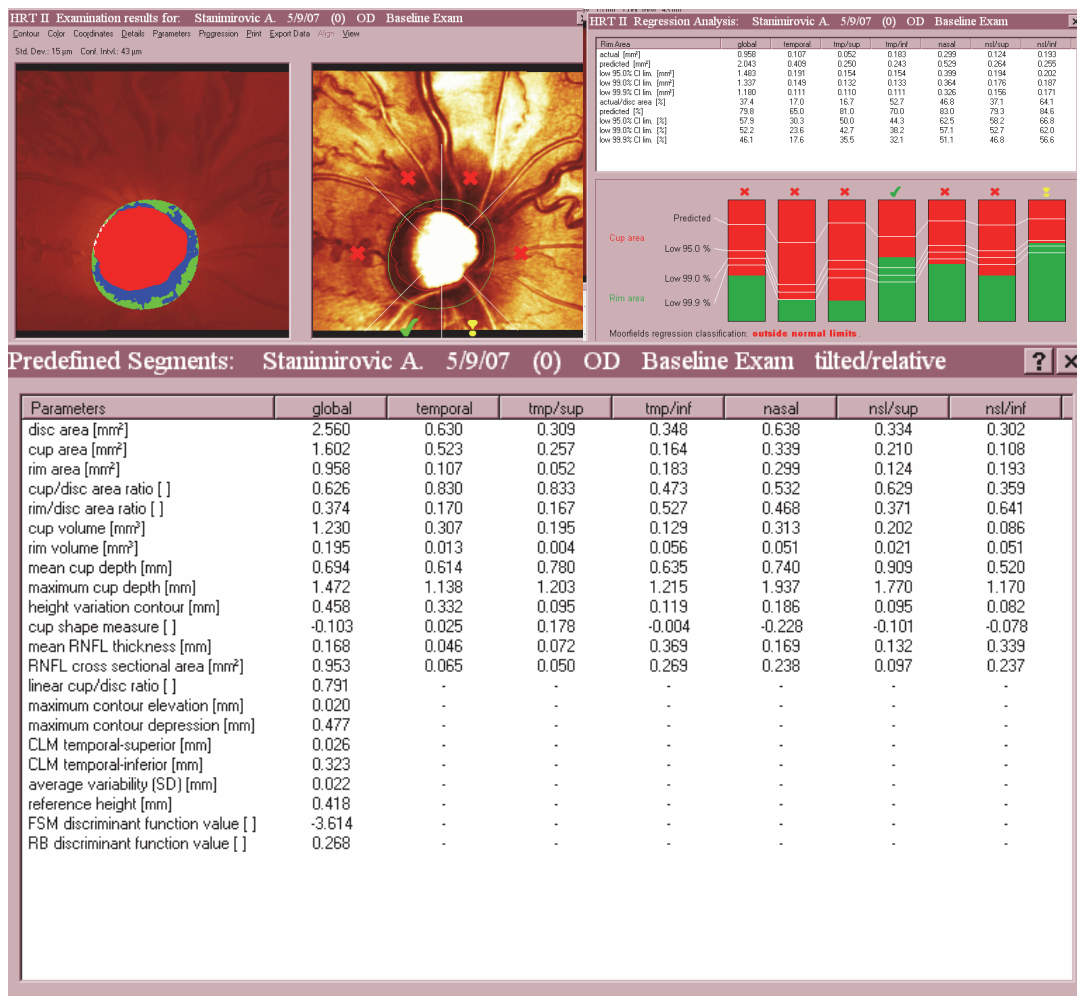


Fig. 4 – Hajdelberg Retina Tomograph II (HRT) initial report of the right eye (OD), neuroretinal rim (NR) was preserved in the Ti segment; NR was damaged in T, Ts, N, Ns segments, and borderline parameters of NR were found in the Ni segment, disc area = 2.560 mm², cup volume 1.230 mm³, cup area = 1.602 mm², mean cup depth = 0.694 mm, max. cup depth = 1.472 mm, rim area 0.958 mm² and rim volume = 0.195 mm³, cup/disc (C/D) ratio = 0.626, linear C/D ratio = 0.791. RNGL – retinal nerve fiber layer; CLM – contour line modulation; FSM – Mikelberg discriminant function; RB – right bank.

Local antiglaucomatous therapy was introduced and during the hospitalisation intraocular pressure normalized. The patient was discharged with the IOP values 16 mmHg in the right eye and 15 mmHg in the left eye without therapy.

On the regular monthly check-ups the right eye IOP varied from 13–30 mmHg in the morning, reaching values up to 50 mmHg in the afternoon in spite of prescribed therapy so the patient was hospitalised again. IOP in *oculi sinistri* (S) was 13–16 mmHg without therapy. HRT II results during the second hospitalization showed progression and decompensation of glaucoma. Since IOP in *oculi dextri* (OD) was not normalized under further therapy, antiglaucomatous surgery (trabeculectomy – TTR), in general anesthesia, was performed during the third hospitalization (Figure 5). Mitomycin C was not used in the procedure in order to avoid postoperative hypotonia because IOP showed significant daily variations.

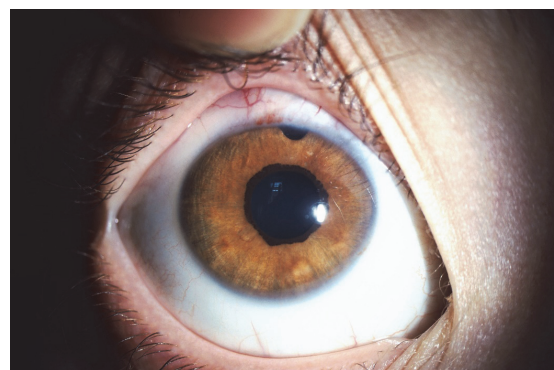


Fig. 5 – Anterior segment of the right eye after the performed antiglaucomatous surgery (trabeculectomy – TTR).

Upon discharge, IOP on the right eye was 8 mmHg with a somewhat enlarged filtration bleb, and 9 mmHg on the left eye.

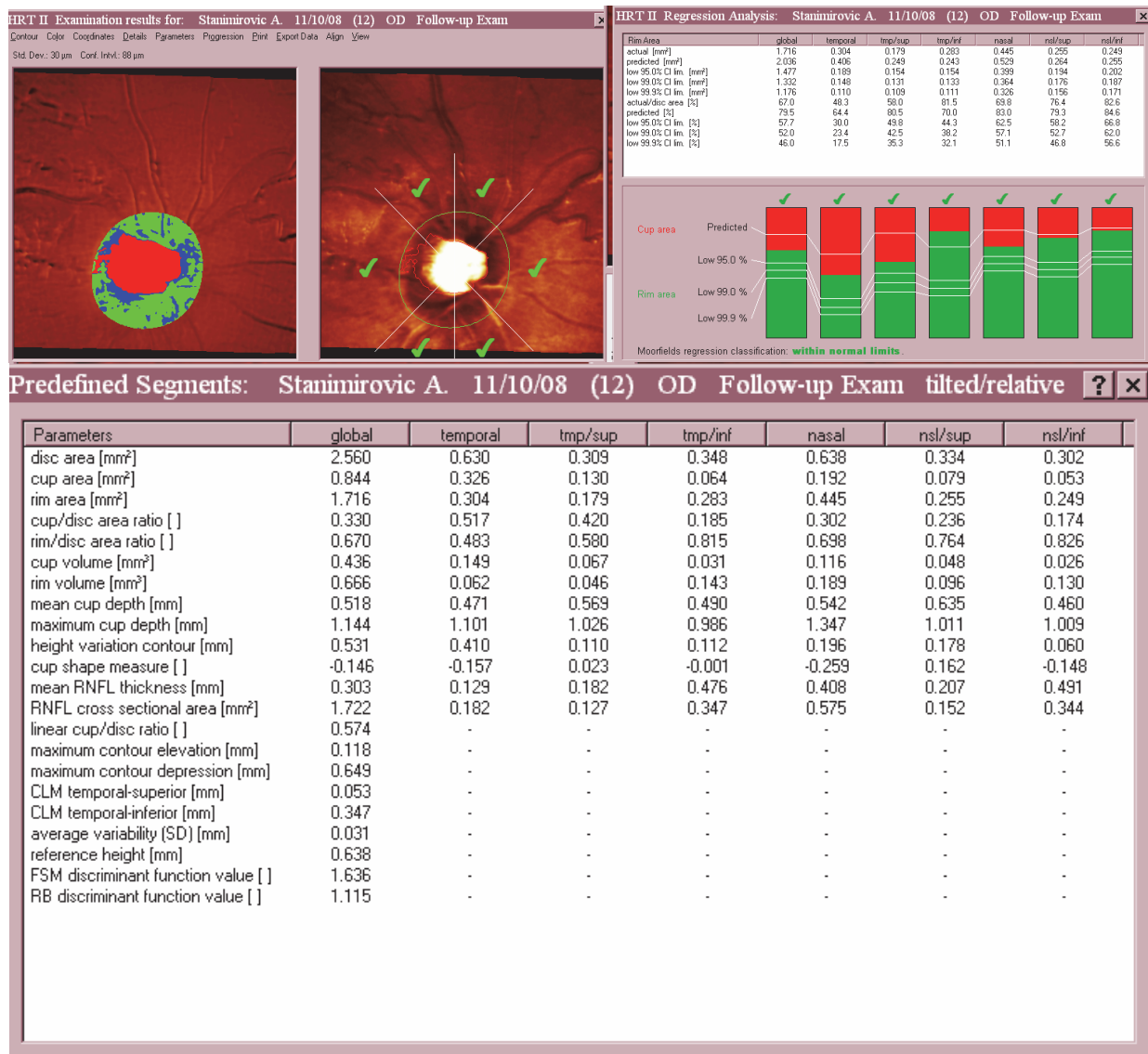


Fig. 6 – Hajdelberg Retina Tomograph II (HRT II) findings 18 months after the trabeculectomy. Values of stereometric parameters were: disc area: 2.560, rim area = 1.716 mm², cup volume = 0.436 mm³, rim volume = 0.666 mm³ mean cup depth = 0.518 mm, max. cup depth = 1.144 mm and cup/disc (C/D) ratio = 0.330 and linear C/D = 0.574. Neuroretinal rim (NR) was preserved in all its segments. Moorfields regression analysis were classified as “within normal limits”. RNFL – retinal nerve fiber layer; CLM – contour line modulation; FSM – Mikelberg discrimination function; RB – right bone.

On the regular check-up 3 months later, IOP values were 10 mmHg on the right, and 11 mmHg on the left eye. Horizontal corneal diameter in OD was 10.5 mm and in OS 10 mm, with no Haab striae. Best corrected visual acuity (BCVA) was 20/20 on both eyes. Three months after the procedure, HRT II examination results were: cup area = 1.156 mm², cup volume = 0.717 mm³, rim area = 1.403 mm², rim volume = 0.495 mm³ and C/D = 0.452, which is evidently lower C/D compared to the initial report.

Figure 6 shows the HRT II results 18 months after the trabeculectomy. The rim area increased to 1.716 mm² (0.958 mm² preoperatively) as well as rim volume which was 0.666 mm³ (0.195 mm³ preoperatively) while C/D decreased to

0.330 (0,626 preoperatively) as well as linear C/D = 0.574 (0.791 preoperatively) (Figure 6). NR rim was found to be preserved in all its segments so the findings of Moorfields regression analysis were classified as “within normal limits”. All this undoubtedly demonstrates the recovery of the NR rim on the optic disc.

Since the patient was without any therapy she had regular check-ups, first on 3, then on 6 months and then once a year. Last check-up was 6 months ago.

BCVA was 20/20 on both eyes, intraocular pressure was 14 mm Hg on the right, and 15 mm Hg on the left eye. Axial length of the right eye was 25 mm and of the left 23.5 mm.

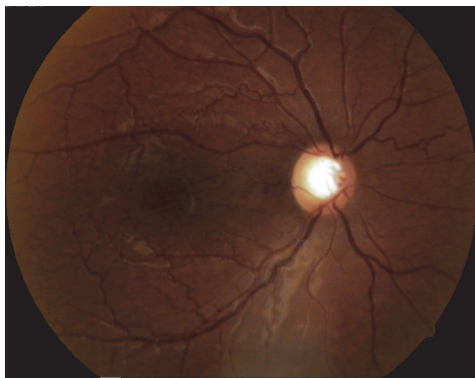


Fig. 7 – Foto fundus right eye – preserved neuroretinal rim (NR), cup/disc (C/D) ratio 0.4.

Foto fundus of the right eye showed preserved rim of the optic head with cup/disc ratio 0.4 and no pathology on the posterior segment of the eye (Figure 7).

Figure 8a presents HRT II of the right eye 9 years after the trabeculectomy. All the findings were within normal limits: HRT II left eye findings (6/1/2016) were C/D = 0.356, linear C/D = 0.597, rim area = 2.164, rim volume = 0.380 mm³, disc area = 3.361 mm². Computerised visual field of the right eye showed generalised reduction of sensitivity MD-3.9 db; Bebie curve cumulative defect curve: diffuse loss of sensitivity under normal curve, but paralleled with displayed normal curve; left eye: normal sensitivity (Figure 8b).

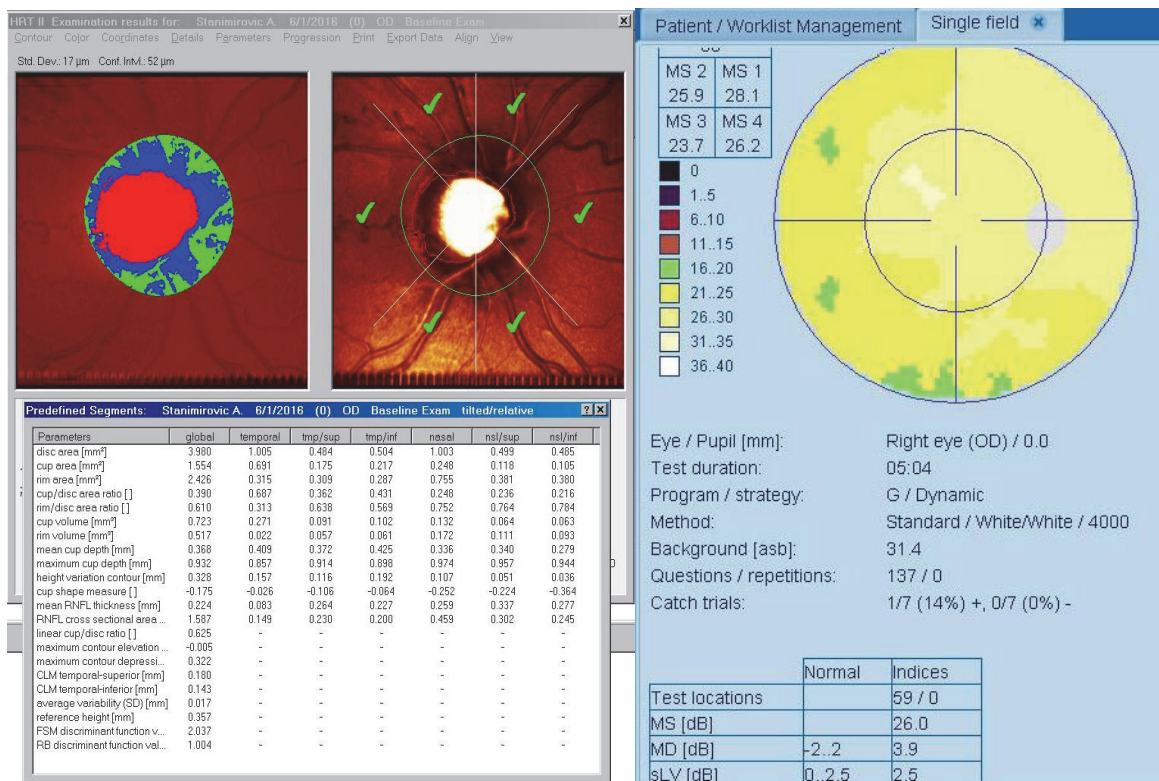


Fig. 8 – a) Haiedelberg Retina Tomograph II (HRTII) cup/disc (C/D) ratio: 0.390, linear C/D = 0.625, rim area = 2.426 mm², rim volume = 0.517 mm³, disc area: 3.980 mm²; b) Computerized visual field of the right eye showed generalised reduction of sensitivity MD-3.9 db, Bebie curve (cumulative defect curve): diffuse loss of sensitivity under normal curve, but paralleled with displayed normal curve.

RNFL – retinal nerve fiber layer; CLM – contour line modulation; FSM – Mikelberg discrimination function; RB – right bank.

Discussion

In the majority of cases from the available literature CEU is associated with glaucoma. Typically, there is an initial drop of IOP following the induction of the topical therapy, like in the case presented, but eventually most cases require filtration surgery.

The origin of the CEU is not certain. Dowling et al. ¹ suggested that abnormal migration of neural crest cells might be the reason for the development of the CEU, while Ritch et al. ² suggested the possibility of a neural crest cell disorder. Some au-

thors describe bilateral CEU with late onset primary glaucoma and bilateral prominent corneal nerves ^{3,4}. Wilson ⁵ concluded that, due to its embryological origin, this trinity supports the neural crest cell theory of the anterior segment dysgenesis.

Harasymowycz et al. ⁶ analysed a sample of an iris taken from the eye with CEU and glaucoma and found a fibro vascular membrane on the front surface of the iris. Its traction might be responsible for pulling the posterior pigmented epithelium and CEU formation. Embryonal heart studies ⁷ suggest the vascular factor being primary insult that leads to the secondary disorder of the neural crest cell migration.

The recovery of the optic nerve is widely discussed. Tavares et al.⁸ found no significant change in anatomic and functional glaucoma evaluation 5–6 months after glaucoma surgery. Wright et al.⁹ suggested that IOP lowering surgery enhances visual field (VF) sensitivity while Ventura et al.¹⁰ found that the progressive loss of retinal ganglion cell function in early glaucoma may be alleviated after IOP lowering, as measured by pattern electroretinograms.

Lesk et al.¹¹ concluded that lowering of the IOP by 40% after glaucoma surgery had improved optic nerve morphology correlating highly with the percent reduction of IOP. Waisbourd et al.¹² also reported cupping reversal and visual field (VF) improvement, but results did not correlate to the amount of the IOP lowering.

Emery et al.¹³ suggested that increased IOP causes bulging of the cribrous lamina posteriorly, rearrangement of the openings on it, strangulation of axons and stagnation of axoplasmic transport. Quigley¹⁴ demonstrated that decrease of the IOP induced cupping reversal and recovery of

the optic nerve head. Mochizuki et al.¹⁵ reported cupping reversal accompanied by the shrinkage of the scleral canal after successful IOP-lowering surgery. If the cupping reversal had not been observed, the scleral ring enlargement and ongoing stress on the optic nerve would have been continued. The cupping reversal is more frequent in children due to a larger number of elastic fibres in the fibrous layer of the globe.

Conclusion

In the presented case, normalisation of IOP induced a cupping reversal and normalized axoplasmic transport resulting in the recovery of neuroretinal rim and the decrease of C/D ratio.

Even in the case of the secondary juvenile glaucoma due to congenital uveal ectropion, early detection and adequate treatment can prevent and reverse optic disc neuropathy.

R E F E R E N C E S

1. Dowling JL, Albert DM, Nelson LB, Walton DS. Primary glaucoma associated with iridotrabeular dysgenesis and ectropion uveae. *Ophthalmology* 1985; 92(7): 912–21.
2. Ritch R, Forbes M, Hetherington J, Harrison R, Podos SM. Congenital ectropion uveae with glaucoma. *Ophthalmology* 1984; 91(4): 326–31.
3. Bansal A, Luck J. Primary iris pigment epithelial hyperplasia and glaucoma. *Br J Ophthalmol* 2002; 86(3): 350–3.
4. Sethi HS, Pal N, Dada T. Bilateral juvenile glaucoma with iridotrabeular dysgenesis, congenital ectropion uveae, and thickened corneal nerves. *Eye (Lond)* 2005; 19(12): 1347–9.
5. Wilson ME. Congenital iris ectropion and a new classification for anterior segment dysgenesis. *J. Paediatr Ophthalmol Strabismus* 1990; 27(1): 48–55.
6. Harasymowycz PJ, Papamatheakis DG, Eagle RC, Wilson RP. Congenital ectropion uveae and glaucoma. *Arch Ophthalmol* 2006; 124(2): 271–3.
7. Compernelle V, Brusselmans K, Franco D, Moorman A, Dewerchin M, Collen D, et al. Cardia bifida, defective heart development and abnormal neural crest migration in embryos lacking hypoxia-inducible factor-1alpha. *Cardiovasc Res* 2003; 60(3): 569–79.
8. Tavares IM, Melo LA Jr, Prata JA Jr, Galbardo R, Paranhos A Jr, Mello PA. No changes in anatomical and functional glaucoma evaluation after trabeculectomy. *Graefes Arch Clin Exp Ophthalmol* 2006; 244(5): 545–50.
9. Wright TM, Goharian I, Gardiner SK, Sebi M, Greenfield DS. Short-term enhancement of visual field sensitivity in glaucomatous eyes following surgical intraocular pressure reduction. *Am J Ophthalmol* 2015; 159(2): 378–85.e1.
10. Ventura LM, Feuer WJ, Porciatti V. Progressive loss of retinal ganglion cell function is hindered with IOP-lowering treatment in early glaucoma. *Invest Ophthalmol Vis Sci* 2012; 53(2): 659–63.
11. Lesk MR, Spaeth GL, Azuara-Blanco A, Araujo SV, Katz LJ, Terebuh AK, et al. Reversal of optic disc cupping after glaucoma surgery analyzed with a scanning laser tomograph. *Ophthalmology* 1999; 106(5): 1013–8.
12. Waisbourd M, Ahmed OM, Molineaux J, Gonzalez A, Spaeth GL, Katz LJ. Reversible structural and functional changes after intraocular pressure reduction in patients with glaucoma. *Graefes Arch Clin Exp Ophthalmol* 2016; 254(6): 1159–66.
13. Emery JM, Landis D, Paton D, Boniuk M, Craig JM. The lamina cribrosa in normal and glaucomatous human eyes. *Trans Am Acad Ophthalmol Otolaryngol* 1974; 78(2): OP290–7.
14. Quigley HA. Childhood glaucoma: Results with trabeculectomy and study of reversible cupping. *Ophthalmology* 1982; 89(3): 219–26.
15. Mochizuki H, Lesley AG, Brandt JD. Shrinkage of the scleral canal during cupping reversal in children. *Ophthalmology* 2011; 118(10): 2008–13.

Received on September 21, 2016.

Revised on November 18, 2016.

Accepted on November 22, 2016.

Online First December, 2016.